

Vagus Associated Neurogenic Cough Occurring Due to Unilateral Vascular Encroachment of Its Root: A Case Report and Proof of Concept of VANCOUVER Syndrome

Annals of Otolaryngology & Laryngology
1–5

© The Author(s) 2019

Article reuse guidelines:

sagepub.com/journals-permissions

DOI: 10.1177/0003489419892287

journals.sagepub.com/home/aor



Christopher R. Honey, MD, DPhil¹ , Marie T. Krüger, MD¹,
Murray D. Morrison, MD², Baljinder S. Dhaliwal, MD³,
and Amanda Hu, MD²

Abstract

Objectives: A patient is presented with neurogenic cough due to a unilateral vascular compression of a vagus nerve rootlet at the brainstem with complete resolution of cough following microvascular decompression of that nerve. This etiology of a neurogenic cough has not been previously reported to our knowledge. The proportion of patients with neurogenic cough refractory to all current therapies and suffering with this treatable condition remains to be defined. We introduce the concept of Vagus Associated Neurogenic Cough Occurring due to Unilateral Vascular Encroachment of its Root (VANCOUVER syndrome) and present the salient features of this condition.

Methods: A case review is presented with details of the patient's history, examination, imaging, laryngoscopy, intraoperative findings, and long-term clinical outcome.

Results: A 60-year-old man presented with a 15-year history of non-productive cough refractory to antibiotics, and anti-reflux medications. Investigations by an allergist, a cardiologist, a gastroenterologist, two pulmonologists, and an otolaryngologist were negative. MRI demonstrated a vascular compression of his left vagus nerve and microvascular decompression of that nerve resolved his symptoms. There were no surgical complications and the patient remains asymptomatic at 1 year.

Conclusions: Neurogenic cough has been likened to a vagus nerve neuropathy in a similar way that trigeminal neuralgia is a trigeminal nerve neuropathy. Both cause intermittent sensory phenomena in their distribution and can be ameliorated with neuropathic medications. We demonstrate that neurogenic cough, like trigeminal neuralgia, may be caused by a vascular compression of its nerve root. A proposed mechanism of this type of neurogenic cough is presented along with a potential diagnostic paradigm for these patients.

Keywords

chronic cough, microvascular decompression, neurogenic cough, vagus nerve, VANCOUVER syndrome

Introduction

We report a case of neurogenic cough due to a unilateral vascular compression of a vagus nerve rootlet at the brainstem with complete resolution of cough following neurosurgical microvascular decompression of that nerve. This etiology of a neurogenic cough has not been previously reported to our knowledge. The presenting characteristics of the patient's cough and its response to multiple standard treatments are presented along with the relevant imaging and surgical findings. This previously unreported but treatable etiology of neurogenic cough will need to be considered for

¹Division of Neurosurgery, Department of Surgery, University of British Columbia, Vancouver, BC, Canada

²Division of Otolaryngology, Department of Surgery, University of British Columbia, Vancouver, BC, Canada

³Department of Anesthesiology, Pharmacology, and Therapeutics, University of British Columbia, Vancouver, BC, Canada

Corresponding Author:

Dr. Christopher R. Honey, MD, DPhil, FRCSC, FACS, Professor of Neurosurgery, UBC, Suite 8105, 2775 Laurel St., Vancouver, BC V5Z 1M9, Canada.

Email: chris.honey@telus.net

the cohort of patients who remain refractory to the current treatments. We present a proposed treatment paradigm for this condition.

Case Report

A 60-year-old, right-handed man presented with a 15-year history of medically refractory, non-productive cough. There was no preceding respiratory tract infection, viral rash, trauma, or exposure to harsh fumes. There was no history of asthma, allergy, or acid reflux. The cough was initially very mild and began with an insidious onset but relentlessly progressed over the years in frequency, duration, and severity. The cough itself was an involuntary and an irresistible response to a “tickling” sensation deep to the suprasternal notch. At its worst, each episode would last approximately 1 minute and could occur six times per hour. The coughing was occasionally severe enough to cause near-syncope and could awaken him from sleep. The cough occurred spontaneously but was triggered by exerting his voice, singing, laughing, exercise, lying down, strong perfume, and during episodes of respiratory infection. In between episodes, he reported his voice was normal. He denied laryngospasm, choking, or throat pain. The coughing interfered with his work and he had been on disability for 6 months during 2016. In 2018, he had a spontaneous easing of symptoms (coughing fits only once per week) for several months and then had a gradual increase in symptoms again.

Past medical history was significant for angina and he had three cardiac stents with chronic antiplatelet therapy (clopidogrel). He had a tonsillectomy in 1962 and myringotomy tubes in 1965. He quit smoking in 1977 after nine pack-years. All allergy testing had been negative. A methacholine challenge was negative. A pH monitor was not tolerated because of a strong gag reflex, but chronic antacids and a proton pump inhibitor (pantoprazole 40 mg po bid) had no benefit. A decade into this chronic cough, he was started on an ACE-inhibitor (ramipril) for hypertension. It was discontinued for 3 months with no benefit and he remains on this potentially cough-inducing medication after surgical resolution of his symptoms. A chest CT was normal. Consultations with an allergist, a cardiologist, two pulmonologists, and an otolaryngologist were unremarkable.

Physical examination revealed no lymphadenopathy and normal cranial nerves. Nasal examination was negative for any sinonasal disease. Laryngoscopy revealed no masses, normal mobility bilaterally, normal mucosal wave, normal vocal cord closure with a small posterior gap, no supraglottic hyperfunction, and no post-cricoid or arytenoid edema or erythema. He scored 20/40 on the Cough Severity Index (CSI)¹ and 93/133 on the Leicester quality of life Cough Questioner (LCQ).² His reflux symptom index³ was normal at 11/45 and his voice handicap index-10 was normal at 0/40.⁴

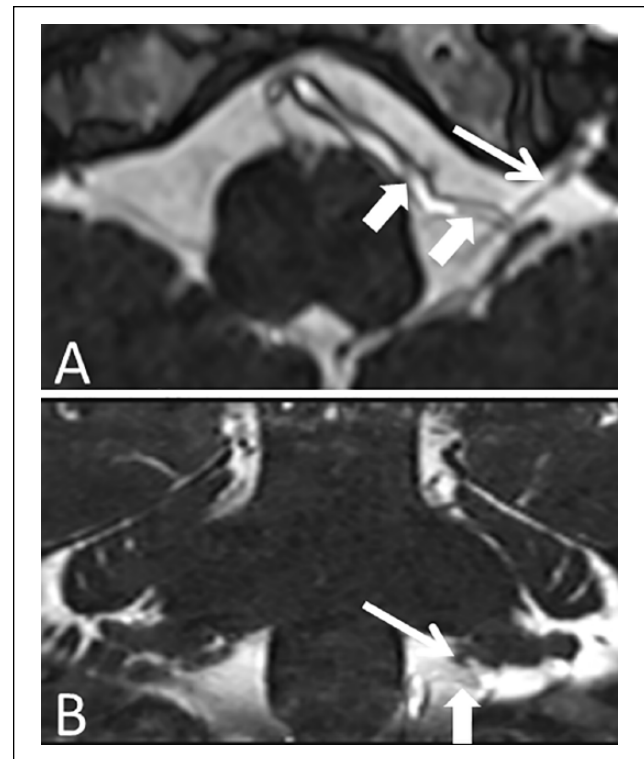


Figure 1. Preoperative MRI brainstem images.

The axial (A) MRI CISS sequence shows the left vagus nerve rootlet (thin arrow) traversing from the brainstem to the jugular fossa. There is a unilateral vascular encroachment of this vagus nerve root by the left posterior inferior cerebellar artery (large arrow). The coronal (B) image shows this vessel is a convex loop as it encroaches the vagus nerve.

A trial of carbamazepine 200 mg daily was initiated with an increase to 200 mg BID after 1 week. During the second week, the patient reported a dramatic 80% reduction in his cough frequency and intensity. However, due to cognitive blunting, emotional lability and suicidal ideation, the carbamazepine was discontinued, and his cough returned. Follow-up psychiatric consultation revealed no previous psychopathy, no suggestion of a conversion disorder or malingering and there were no further depressive symptoms following discontinuation of that medication. A second trial with gabapentin or amitriptyline was refused.

A brain MRI was performed. Our recent experience with vascular compression of the vagus nerve rootlets causing cough associated with hemi-laryngopharyngeal spasm prompted this neuroimaging.⁵ The CISS sequence (see Figure 1) demonstrated a unilateral vascular encroachment of a vagus nerve rootlet at the left brainstem. Breathing humidified air with 5 cc of nebulized 1% lidocaine stopped all cough for approximately 8 hours. Staged left and then (1 week later) right unilateral superior laryngeal nerve block⁶ had no benefit. Staged left and then (1 hour later) right bronchial ventilation with 5 cc of nebulized 2% lidocaine during propofol general anesthetic had no subjective benefit following extubation.

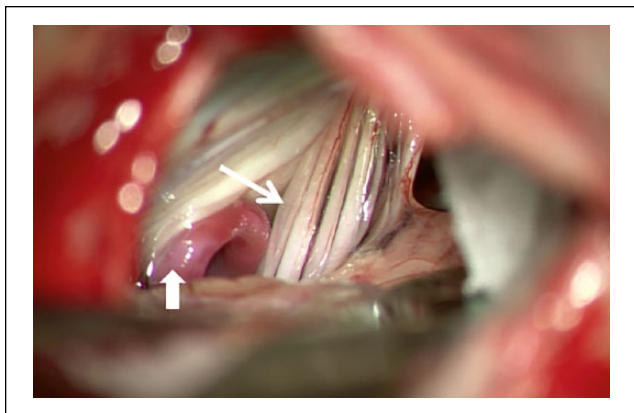


Figure 2. Intraoperative view showing vascular encroachment of a vagus nerve rootlet.

The looping posterior inferior cerebellar artery (large arrow) had its convex apex against the caudal rootlet of the left vagus nerve (thin arrow) and was encroaching on the nerve from anterior and inferior (as predicted from the MRI). The vessel has been moved slightly laterally, out from behind the nerve, in order to see it.

Table 1. Pre- and Postoperative Cough Severity Index (CSI) and Leicester Cough Questionnaire (LCQ).

	Preoperative	6 weeks Postoperative	6 months Postoperative
CSI	20/40	3/40	2/40
LCQ	93/133	127/133	130/133

Neurosurgical exploration of the left lower brainstem confirmed severe encroachment of a rootlet of the left vagus nerve (see Figure 2) by a loop of the posterior inferior cerebellar artery (PICA). A microvascular decompression was performed moving the PICA away from the vagus and securing it anteromedially with Teflon and Tiseel.

The patient had coughing in the postoperative recovery room but none after returning to the ward a few hours later. The following day he could sing and project his voice without cough. He has remained free of his previous pathological cough for 1 year. His pre- and postoperative CSI and LCQ scores are shown in Table 1. The severity of his cough improved (lower CSI scores) and his quality of life improved (higher LCQ scores). He has had rare cough which he felt was appropriate for the situation (eg, after choking on some water). There was no postoperative dysphonia, dysphagia, dysarthria, or limb dysmetria. Laryngoscopy revealed normal vocal cord function at 6 weeks postoperative.

Discussion

In a recent review, Altman et al⁷ defined neurogenic cough as,

“a chronic cough (more than 8 weeks duration) in the absence of typical external stimuli to the cough mechanism, and thus is by definition a diagnosis of exclusion, possible only after the extensive investigations to eliminate the possibility of other causes.”

The American College of Chest Physicians (ACCP) recommends that these investigations include those for sinonasal disease, asthma, nonasthmatic eosinophilic bronchitis, and gastroesophageal reflux disease.⁸

Recent theories regarding the etiology of neurogenic cough have focused on a sensory neuropathic hypersensitivity.^{7,9-12} These theories are supported by the clinical similarities between trigeminal neuralgia and neurogenic cough.^{9,13} Bastion et al¹⁰ crystallized this idea when they speculated that,

‘a vagal neuralgia could manifest as a sudden and exaggerated, but nonpainful sensation that the vagus nerve normally mediates – a bogus tickle that leads to uncontrollable coughing.’

Continuing the analogy of neurogenic cough to trigeminal neuralgia, we propose that one possible cause of neurogenic cough may be a vascular compression of a vagus nerve rootlet. Compression of the trigeminal nerve by a vessel is the most common cause of trigeminal neuralgia.¹⁴ Our team has managed over a thousand patients with trigeminal neuralgia and are familiar with both its pharmacological management and potential neurosurgical cure—microvascular decompression. Surgery is reserved for those who either cannot control the pain with medications or cannot tolerate the side-effects of the medications required to control the neuralgia.

Patients with neurogenic cough may respond to gabapentin,¹⁵ amitriptyline,¹⁶ pregabalin,¹⁷ tramadol,¹⁸ and non-pharmacologic intervention, like speech therapy.¹⁷ A subset of these patients may have VANCOUVER syndrome (Vagus Associated Neurogenic Cough due to Unilateral Vascular Encroachment of its Root) and, if refractory to medical treatment, could potentially benefit from microvascular decompression.

This single case report may serve as an initial proof of concept and provide some insight into the symptomatology and pathophysiology of this rare syndrome. A prospective case series will be needed to confirm this theory. The failure of all the multiple previous medical therapies and the lack of any psychiatric history reduces the likelihood that the results were due to a placebo effect.

A definitive test will be required to exclude incidental contact of a vessel against the vagus nerve in a patient with chronic cough from a different etiology. Our previous MRI study reported that this incidental contact may be as high as 50% in asymptomatic individuals.¹⁹ We are prospectively evaluating sequential unilateral proximal vagus nerve block

as the diagnostic test of choice. Cessation of cough following a unilateral vagus nerve block ipsilateral but not contralateral to an MRI confirmed vascular compression may be the definitive test for VANCOUVER syndrome. In the case reported, we tried unsuccessfully to determine if relatively routine tests (unilateral superior laryngeal nerve block⁶ or unilateral bronchial ventilation with lidocaine) could eliminate the symptoms. Unfortunately, these two tests do not cover the entire respiratory sensory region of the vagus nerve. A unilateral positive response could have confirmed the diagnosis, but a negative response did not rule it out. Ultimately, our patient understood preoperatively that, although there was a vessel encroaching his left vagus nerve, decompressing it may not have stopped his cough.

Vascular compression of the trigeminal nerve causes a focal demyelination at the site of compression and allows ephaptic transmission from nerve fibers conveying touch (A β) to those fibers transmitting sharp (A δ) or burning (C) pain.¹⁴ Laryngeal and tracheobronchial sensory afferents travel to the brainstem (nucleus tractus solitarius) through the vagus nerve. A similar compression of the vagus could potentially allow ephaptic transmission from fibers transmitting information from non-cough receptors (eg, rapidly adapting receptors, slowly adapting receptors) to those from cough receptors.

More than 80% of the vagus nerve is sensory but it also carries motor fibers (eg, to the muscles of the pharynx and larynx). If ephaptic transmission of electrical signals traveling in the vagus nerve crossed over to those motor fibers, then patients would also present with hemi-laryngopharyngeal spasm and coughing. This syndrome has been recently reported in a case report²⁰ and a case series.⁵

Conclusion

We propose that vascular compression of a vagus nerve rootlet can cause a “vagus neuralgia” that manifests as a tickling sensation deep to the suprasternal notch and triggers a chronic, non-productive, neurogenic cough. This cough is refractory to antibiotics, anti-reflux medications, speech therapy, and psychotherapy but responds to anti-neuralgia medications. It has a relentless progression but, like trigeminal neuralgia, may have spontaneous remissions and relapses. The diagnosis may require MRI confirmation of a vascular compression of the vagus as well as a unilateral benefit from a vagus nerve block. Microvascular decompression of the nerve offers a high chance of cure but has inherent risks related to neurosurgery near the brainstem.


Declaration of Conflicting Interests

The author(s) declared no potential conflicts of interest with respect to the research, authorship, and/or publication of this article.

Funding

The author(s) received no financial support for the research, authorship, and/or publication of this article.

ORCID iD

Christopher R. Honey  <https://orcid.org/0000-0003-2601-6652>

References

1. Shember AC, Rosen CA, Zullo TG, Gartner-Schmidt JL. Development and validation of the cough severity index: a severity index for chronic cough related to the upper airway. *Laryngoscope*. 2013;123:1931-1936.
2. Birring S, Prudon B, Carr A, Singh S, Morgan M, Pavord I. Development of a symptom specific health status measure for patients with chronic cough: Leicester Cough Questionnaire (LCQ). *Thorax*. 2003;58:339-343.
3. Belafsky PC, Postma GN, Koufman JA. Validity and reliability of the reflux symptom index (RSI). *J Voice*. 2002;16:274-277.
4. Rosen CA, Lee AS, Osborne J, Zullo T, Murry T. Development and validation of the voice handicap index-10. *Laryngoscope*. 2004;114:1549-1556.
5. Honey CR, Morrison MD, Heran MKS, Dhaliwal BS. Hemi-laryngopharyngeal spasm as a novel cause of inducible laryngeal obstruction with a surgical cure: a report of 3 cases [published online July 1, 2018]. *J Neurosurg*. doi:10.3171/2018.2.JNS172952
6. Simpson CB, Tibbetts KM, Loochtan MJ, Dominguez LM. Treatment of chronic neurogenic cough with in-office superior laryngeal nerve block. *Laryngoscope*. 2018;128:1898-1903.
7. Altman KW, Noordzij JP, Rosen CA, Cohen S, Sulica L. Neurogenic cough. *Laryngoscope*. 2015;125:1675-1681.
8. Gibson P, Wang G, McGarvey L, Vertigan AE, Altman KW, Birring SS. Treatment of unexplained chronic cough: CHEST guideline and expert panel report. *Chest*. 2016;149:27-44.
9. Lee B, Woo P. Chronic cough as a sign of laryngeal sensory neuropathy: diagnosis and treatment. *Ann Otol Rhinol Laryngol*. 2005;114:253-257.
10. Bastian RW, Vaidya AM, Delsupehe KG. Sensory neuropathic cough: a common and treatable cause of chronic cough. *Otolaryngol Head Neck Surg*. 2006;135:17-21.
11. Vertigan AE, Gibson PG. Chronic refractory cough as a sensory neuropathy: evidence from a reinterpretation of cough triggers. *J Voice*. 2011;25:596-601.
12. Cohen SM, Misono S. Use of specific neuromodulators in the treatment of chronic, idiopathic cough: a systematic review. *Otolaryngol Head Neck Surg*. 2013;148:374-382.
13. Amin MR, Koufman JA. Vagal neuropathy after upper respiratory infection: a viral etiology? *Am J Otolaryngol*. 2001;22:251-256.
14. Hilton DA, Love S, Gradidge T, Croakham HB. Pathological findings associated with trigeminal neuralgia caused by vascular compression. *Neurosurgery*. 1994;35:299-303.

15. Ryan NM, Birring SS, Gibson PG. Gabapentin for refractory chronic cough: a randomized, double-blind, placebo-controlled trial. *Lancet*. 2012;380:1583-1589.
16. Jeyakumar A, Brickman TM, Haben M. Effectiveness of amitriptyline versus cough suppressants in the treatment of chronic cough resulting from postviral vagal neuropathy. *Laryngoscope*. 2006;116:2108-2112.
17. Vertgan AE, Kapela SL, Ryan NM, Birring SS, McElduff P, Gibson PG. Pregabalin and speech pathology combination therapy for refractory chronic cough: a randomized controlled trial. *Chest*. 2016;149:639-648.
18. Dion GR, Teng SE, Achlatis E, Fang Y, Amin MR. Treatment of neurogenic cough with tramadol: a pilot study. *Otolaryngol Head Neck Surg*. 2017;157:77-79.
19. Avcillas-Chasin J, Kozoriz MG, Shewchuk JR, Heran MKS, Honey CR. Imaging and surgical findings in patients with hemilaryngopharyngeal spasm and the potential role of MRI in the diagnostic work-up. *Am J Neuroradiol*. 2018;39:2366-2370.
20. Honey CR, Gooderham P, Morrison M, Ivanishvili Z. Episodic hemilaryngopharyngeal spasm (HELPS) syndrome: case report of a surgical treated novel neuropathy. *J Neurosurg*. 2017;126:1653-1656.